

Partial hydatidiform mole at 17 weeks gestation with HELLP Syndrome: the preventive role of the first-trimester screening

Mola hidatidiforme parcial às 17 semanas de gestação com Síndrome de HELLP: o papel do rastreio de 1.º trimestre na prevenção

Diana Margarida Monteiro¹, Mariana Dória¹, Inês Sarmiento Gonçalves¹, João Pedro Neves¹
Unidade Local de Saúde de Matosinhos – Hospital Pedro Hispano

Abstract

HELLP Syndrome is one of the most severe forms of hypertensive disorders of pregnancy and is most commonly diagnosed in the third trimester. We present a rare case of a progressive partial hydatidiform mole pregnancy at 17 weeks gestation complicated by HELLP Syndrome. We aim to raise awareness of the key findings at the first-trimester prenatal screening to suspect molar pregnancies and how appropriate prenatal counselling for couples may affect their choices and outcomes. Diagnosing a molar pregnancy as early as possible is of utmost importance to prevent this serious pregnancy-related complication with a high risk of maternal morbimortality.

Keywords: Partial hydatidiform mole; HELLP Syndrome; Triploidy, HCG-beta.

Resumo

O Síndrome de HELLP é uma das doenças hipertensivas da gravidez mais graves e é mais frequente no terceiro trimestre. Apresentamos o caso duma gravidez molar parcial evolutiva às 17 semanas de gestação, complicada de Síndrome de HELLP. Pretendemos alertar para alterações que podem estar associadas a uma gravidez molar no rastreio pré-natal de primeiro trimestre e como o aconselhamento do casal pode afetar suas escolhas e o desfecho. O diagnóstico precoce de gravidez molar é fundamental para prevenir complicações da gravidez associadas a elevada morbimortalidade.

Palavras-chave: Mola hidatidiforme parcial; Síndrome de HELLP; Triploidia; Beta-hCG.

INTRODUCTION

Preeclampsia is a pregnancy-associated disorder classically defined as newly-onset hypertension and proteinuria after 20 weeks' gestation and most frequently in the third trimester¹. The onset of hemolysis, elevated liver enzymes and low platelet count (HELLP) Syndrome is one of the more severe and rarer forms of preeclampsia and is associated with even higher rates

of maternal morbimortality¹⁻⁴. When symptoms associated with hypertensive disorders of pregnancy (HDP) arise before 20 weeks' gestation, the presence of a molar pregnancy should be excluded.

Molar pregnancy or hydatidiform mole (HM) is a premalignant disease that arises from gestational tissue and is classified as either partial (PM) or complete mole (CM)⁵. A PM is formed by triploid cells that most commonly result from the fertilization of an ovum by two sperms or, more rarely, a diploid sperm^{5,6}. In this entity, foetal tissue is present and cardiac activity may develop.

1. Hospital Pedro Hispano.

Ultrasound diagnosis is challenging, with the majority of cases remaining unsuspected after routine ultrasound examination, where a foetus with vitality and regular size may be visualized and placental hydropic structures or increased echogenicity absent or subtle⁷⁻⁹. These changes may become more evident in the second trimester, which may include a mildly growth-restricted foetus with proportionate head size or slight microcephaly and an enlarged and multicystic placenta¹⁰. Therefore, only 18-29% of cases are diagnosed before histopathological evaluation, being misdiagnosed as spontaneous or incomplete abortion^{8,11,12}. PM displays elevated β -human chorionic gonadotropin (β -hCG), but is significantly less noticeable than CM and therefore less likely to present with hyperemesis, hyperthyroidism or theca lutein cysts¹¹.

Despite the high frequency of early miscarriage due to the underlying chromosomal anomaly, some pregnancies continue to progress¹³. It is uncommon for a PM to reach the second trimester, but in such cases of a live foetus the risk of preeclampsia is increased, therefore diagnosis should be made as soon as possible to prevent the severe risk of maternal morbimortality¹¹. Should the diagnosis of PM be made with a live foetus, taking into account the serious threat to the mother's health, couples should be advised to terminate the pregnancy without delay after maternal stabilization^{4,6,11,14}.

CASE REPORT

We present the case of a primigravida in her early 30s, with previously known well-controlled asthma and no other relevant medical history. At 17 weeks gestation, she was transferred to our Hospital from her Primary Health Care Unit where severe hypertension (220/180 mmHg) was detected on a routine visit. She complained of peripheral oedema up to the knees, with progressive worsening, over the last 2 weeks. Additionally, she reported episodes of epigastric pain, indigestion and vomiting during the same period. She denied having headaches, blurred vision or other accompanying symptoms. On physical examination, she presented persistent severe hypertension (185/120 mmHg) and bilateral soft peri-malleolar oedema. She had no other

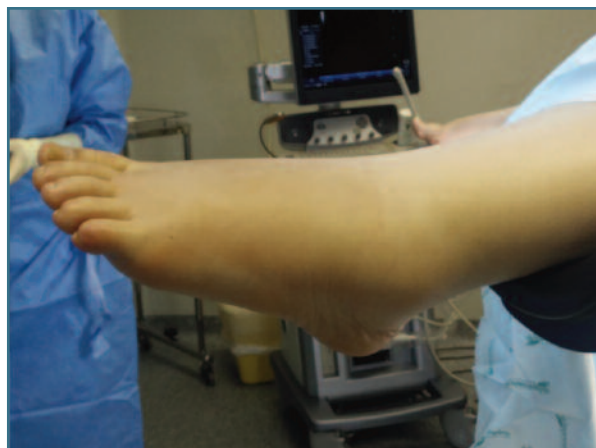

FIGURE 1. Peri-malleolar oedema at admission to the Hospital.

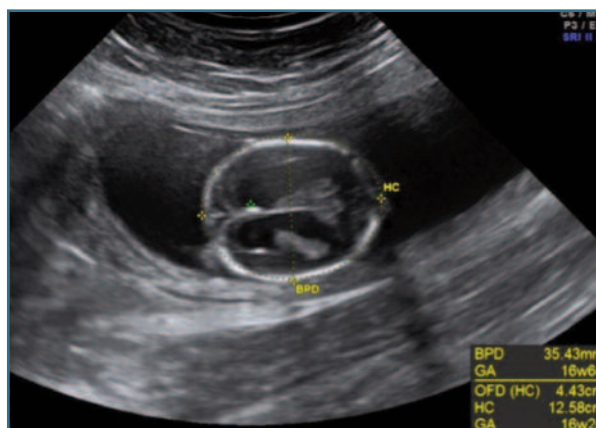


FIGURE 2. Transventricular view of foetal cranium at 17 weeks gestation – suspected agenesis of corpus callosum and bilateral ventriculomegaly.

relevant findings, namely neurologic symptoms, ocular changes, or genital bleeding (Figure 1).

On the ultrasound, the foetus had good vitality and normal amniotic fluid and foetal biometry but agenesis of the corpus callosum and bilateral ventriculomegaly was suspected (Figure 2). The placenta was enlarged and showed numerous cystic lesions (Figure 3). On the transvaginal ultrasound, both ovaries were enlarged (56- and 64-mm largest diameter, respectively), with multiple cysts, suggestive of theca lutein cysts (Figure 4). The urine dipstick test showed 3+ for proteinuria. Blood analysis showed hemoglobin 11.8 g/dl, platelet count was 163 (150-400) $10^9/L$, aspartate aminotransferase activity (AST) 179 (<34) U/L, alanine aminotransferase activity (ALT) 114 (<55) U/L, lacta-

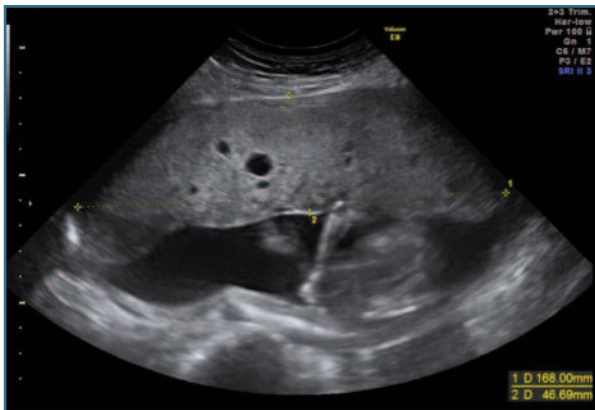


FIGURE 3. Enlarged placenta with multiple cysts.

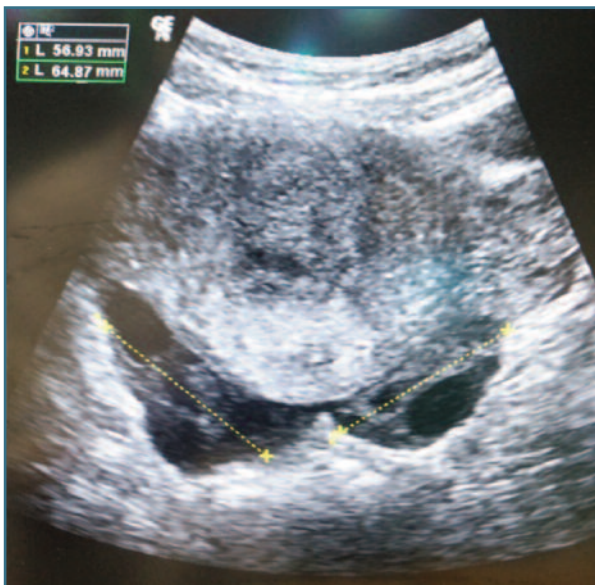

FIGURE 4. Transabdominal view after uterine evacuation – bilaterally enlarged ovaries (56- and 64-mm largest diameter, respectively), with multiple cysts, suggestive of theca lutein cysts.

te dehydrogenase (LDH) 454 (<220) U/L and uric acid 6.5 (<6.0) mg/dL, thyroid stimulating hormone (TSH) 0.23 (0.35-4.94) μ UI/mL, but normal free thyroxine (T4) and severely increased β -hCG (646.000 mUI/ml), with no other relevant changes.

Upon review of prenatal records undertaken in another hospital, the first-trimester ultrasound at 12 weeks and 1 day showed no relevant morphologic foetal or placental anomaly and had nuchal translucency (NT) below the 95th percentile. The combined screening for foetal aneuploidy showed an increased risk for trisomy

21 (1:157) due to increased β -hCG (7,39 multiples-of-median (MoM)) and after counselling at the time, the couple had chosen to perform a non-invasive prenatal test (cell-free foetal DNA (cfDNA)) instead of an amniocentesis, which was negative for trisomy 21, 18 and 13.

The combination of symptoms (hypertension and peripheral oedema), analytical abnormalities (elevated β -hCG), typical cystic lesions of the placenta and theca-lutein ovarian cysts rapidly pointed the team to the diagnosis of a probable HDP in a PM.

She was admitted to the intensive care unit due to the difficult management of hypertension. She was medicated with labetalol protocol, with suboptimal effect and less than 12 hours later her general medical condition worsened, with anemia (8.9 g/dl hemoglobin), thrombocytopenia $64 \times 10^9/L$, AST/ALT 612/285 U/L, LDH 1265 U/L and slightly elevated bilirubin. After multidisciplinary counselling of the couple, termination of the pregnancy was decided due to findings consistent with HELLP syndrome in a pregnancy before the limit of foetal viability. An ultrasound-guided dilation and evacuation under general anesthesia were performed without complications. Magnesium sulfate perfusion was initiated for 24 hours and hypertension was managed with labetalol and posteriorly captopril and amlodipine.

After pregnancy evacuation and initial worsening of anemia (nadir 6.2 g/dl hemoglobin) and thrombocytopenia (nadir $30 \times 10^9/L$), requiring transfusion of one unit of red blood cells, she progressively improved all clinical parameters and was discharged after 8 days. Foetal necropsy showed arachnodactyly of the hands, bilateral “sandal gap” and camptodactyly of the 2nd and 4th toes of the left foot and foetal karyotype revealed a 69, XXY. β -hCG became negative after 2 months and she maintained analytic surveillance for another 6 months. Four years later, she had a healthy baby, with no pregnancy complications.

DISCUSSION

HDP are a major cause of maternal and foetal morbidity and every effort should be made to screen, treat and manage these women with the utmost care¹.

New-onset hypertension or worsening of chronic hypertension during pregnancy, before 20 weeks gestation, should prompt exclusion of maternal underlying conditions that may worsen with pregnancy, such as antiphospholipid syndrome, thrombotic thrombocytopenic purpura, hemolytic-uremic syndrome, systemic lupus erythematosus and other autoimmune diseases and renal conditions^{1,15}. With the introduction of ultrasound as part of routine evaluation of pregnant women, the frequency of late diagnosis of HM and its associated complications have decreased. Nonetheless, preeclampsia-like symptoms in a pregnant woman before 20 weeks mandates exclusion of molar pregnancy⁸. In our case, the patient had a PM that progressed into the second trimester and eventually developed one of the most severe forms of the HDP spectrum – a HELLP Syndrome. It is a rare condition that poses an even higher risk of morbimortality than other HDP.

Early diagnosis of PM and CM does not result in reduction of the risk of progression to gestational trophoblastic neoplasia, but early evacuation significantly decreases the risk of clinical complications such as preeclampsia, so every effort should be made to diagnose these cases as early as possible^{12,20}.

This couple chose to perform a cfDNA test, due to the lower risk of abortion compared to an invasive technique, which was negative for the specific chromosomal abnormalities screened (trisomy 21, 18 and 13). Instead, the performance of an invasive technique would have resulted in an earlier diagnosis of triploidy on the karyotype.

The debate has emerged over the role of cfDNA as the primary screening program for aneuploidies and the potentially missed foetal anomalies beyond trisomy 21, 18 and 13 versus combined first-trimester screening based on ultrasound evaluation (NT and foetal heart rate (FHR)) and maternal serum biochemical markers (free β -hCG and pregnancy-associated plasma protein-A (PAPP-A))^{16,17}.

Regarding sonographic markers (NT or FHR), triploid fetuses do not display significant differences to euploid fetuses¹⁸. As for biochemical markers, though free β -hCG may be elevated in trisomy 21, leading to a high-risk result in the first-trimester screening test for aneuploidies, severe elevations should raise suspicion of other anomalies, such as diandric triploidy (pa-

ternal origin)¹². According to the literature, free β -hCG on trisomy 21 fetuses deviates from euploid 2.2 MoM (range 1.5-3.3 MoM), where diandric triploid fetuses deviate 8.7 MoM (range 2.8-47.0 MoM)^{10,17}.

Analysis of the first-trimester screening result should go beyond the risk value for trisomy 21, 18 and 13. Careful ponderation of free β -hCG and PAPP-A values should be independently interpreted and contextualized.^{17,19}

This clinical presentation of a serious condition, such as the HELLP Syndrome, on a currently rare diagnosis on the 2nd trimester, highlights the importance of being aware of the possibility of a PM, in order to advise rapid termination of pregnancy, given its high risk of morbimortality. In addition, this case makes us ponder the role of each obstetric innovation and the importance of an adequate counselling of cfDNA limitations.

With each generation, Fetal Medicine and Prenatal Diagnosis Specialists have more knowledge and diagnostic tools at their disposal. However, these innovations require clinical sense and wisdom for a correct interpretation. Prenatal counselling of the couple should be done based on all parameters to advise for either routine surveillance, expectant management, cfDNA test or invasive technique (either chorionic vilus sampling or amniocentesis).

REFERENCES

1. Gestational Hypertension and Preeclampsia: ACOG Practice Bulletin, Number 222. *Obstet Gynecol* 2020 Jun;135(6):e237-e260
2. Joshi D, James A, Quaglia A, Westbrook RH, Heneghan MA. Liver disease in pregnancy. *Lancet* 2010 Feb 13;375(9714):594-605
3. Barton JR, Sibai BM. Diagnosis and management of hemolysis, elevated liver enzymes, and low platelets syndrome. *Clin Perinatol* 2004 Dec;31(4):807-33, vii
4. Sibai BM, Ramadan MK, Usta I, Salama M, Mercer BM, Friedman SA. Maternal morbidity and mortality in 442 pregnancies with hemolysis, elevated liver enzymes, and low platelets (HELLP syndrome). *Am J Obstet Gynecol* 1993 Oct;169(4):1000-6
5. Vassilakos P, Riotton G, Kajji T. Hydatidiform mole: two entities. A morphologic and cytogenetic study with some clinical consideration. *Am J Obstet Gynecol* 1977 Jan 15;127(2):167-70
6. Szulman AE, Surti U. The syndromes of hydatidiform mole. I. Cytogenetic and morphologic correlations. *Am J Obstet Gynecol* 1978 Jul 15;131(6):665-71
7. Falkert A, Yildiz A, Seelbach-Goebel B. Partial mole with fetal triploidy as a cause for imminent HELLP-syndrome at 16 weeks of gestation. *Arch Gynecol Obstet* 2009 Mar;279(3):423-5
8. Fowler DJ, Lindsay I, Seckl MJ, Sebire NJ. Routine pre-evaluation ultrasound diagnosis of hydatidiform mole: experience of

more than 1000 cases from a regional referral center. *Ultrasound Obstet Gynecol* 2006 Jan;27(1):56-60

9. Fine C, Bundy AL, Berkowitz RS, Boswell SB, Berezin AF, Doubilet PM. Sonographic diagnosis of partial hydatidiform mole. *Obstet Gynecol* 1989 Mar;73(3 Pt 1):414-8

10. Kagan KO, Anderson JM, Anwandter G, Neksasova K, Nicolaides KH. Screening for triploidy by the risk algorithms for trisomies 21, 18 and 13 at 11 weeks to 13 weeks and 6 days of gestation. *Prenat Diagn* 2008 Dec;28(13):1209-13

11. Sun SY, Melamed A, Joseph NT, Gockley AA, Goldstein DP, Bernstein MR, et al. Clinical Presentation of Complete Hydatidiform Mole and Partial Hydatidiform Mole at a Regional Trophoblastic Disease Center in the United States Over the Past 2 Decades. *Int J Gynecol Cancer* 2016 Feb;26(2):367-70

12. Sebire NJ. The diagnosis of gestational trophoblastic disease in early pregnancy: implications for screening, counselling and management. *Ultrasound Obstet Gynecol* 2005 May;25(5):421-4

13. Berkowitz RS, Goldstein DP, Bernstein MR. Natural history of partial molar pregnancy. *Obstet Gynecol* 1985 Nov;66(5):677-81

14. Snyder S. Major changes in diagnosis and management of preeclampsia. *J Midwifery Womens Health* 2014 Nov-Dec;59(6):596-605

15. Berry EL, Iqbal SN. HELLP Syndrome at 17 Weeks Gestation: A Rare and Catastrophic Phenomenon. *J Clin Gynecol Obstet* 2014 Dec;3(4):147-150

16. Norton ME, Baer RJ, Wapner RJ, Kuppermann M, Jelliffe-Pawlowski LL, Currier RJ. Cell-free DNA vs sequential screening for the detection of fetal chromosomal abnormalities. *Am J Obstet Gynecol* 2016 Jun;214(6):727.e1-6

17. Syngelaki A, Pergament E, Homfray T, Akolekar R, Nicolaides KH. Replacing the combined test by cell-free DNA testing in screening for trisomies 21, 18 and 13: impact on the diagnosis of other chromosomal abnormalities. *Fetal Diagn Ther* 2014;35(3):174-84

18. Kagan KO, Wright D, Valencia C, Maiz N, Nicolaides KH. Screening for trisomies 21, 18 and 13 by maternal age, fetal nuchal translucency, fetal heart rate, free beta-hCG and pregnancy-associated plasma protein-A. *Hum Reprod* 2008 Sep;23(9):1968-75

19. Shiefa S, Amargandhi M, Bhupendra J, Moulali S, Kristine T. First Trimester Maternal Serum Screening Using Biochemical Markers PAPP-A and Free -hCG for Down Syndrome, Patau Syndrome and Edward Syndrome. *Indian J Clin Biochem* 2013 Jan;28(1):3-12

20. Braga A, Moraes V, Maestá I, Júnior JA, Rezende-Filho J, Elias K, et al. Changing Trends in the Clinical Presentation and Management of Complete Hydatidiform Mole Among Brazilian Women. *Int J Gynecol Cancer* 2016 Jun;26(5):984-90

AUTHOR CONTRIBUTION STATEMENT

DM, MD and ISG were directly responsible for the initial approach to the patient in the emergency department and surgical approach; JPN was responsible for the long-term follow-up of the patient. All authors were major contributors to writing the manuscript. All authors read and approved the final manuscript.

CONFLICT OF INTEREST

The authors have no conflicts of interest to disclose.

INFORMED CONSENT

Patient consent was obtained in writing.

CORRESPONDENCE TO:

Diana Margarida Monteiro
E-mail: diana_monteiro_@hotmail.com
<https://orcid.org/0000-0001-9238-7158>

RECEIVED: 04/10/2022

ACCEPTED: 21/01/2023