

A 7-year-old girl with vaginal burn from exposure to an alkaline battery

Rapariga de 7 anos com queimadura vaginal por exposição a pilhas alcalinas

Ana Catarina Massa*, Madalena Tavares*, Tânia Carvalho**, Mafalda Simões***

Maternidade Dr. Alfredo da Costa - Centro Hospitalar de Lisboa Central
Hospital Vila Franca de Xira

Abstract

Background: Vaginal burns resulting from alkaline batteries are a rare and potential serious complication which require a prompt intervention.

Case: A 7-year-old girl presented to the emergency department with lower abdominal pain, dysuria and brownish vaginal discharge. Clinical history suggested a foreign body. Abdominal radiography showed two alkaline batteries inside the vagina that were removed. Vaginotomy revealed severe vaginal burns with necrosis of a large area of posterior cul de sac. Two months after the girl was asymptomatic.

Discussion: Vaginal foreign bodies should be considered in pre-pubertal girls presenting with vaginal bleeding. Its removal and assessment of direct effects should be immediately performed.

Keywords: Foreign body; Pediatric population; Vaginal burn; Alkaline batteries

INTRODUCTION

The ingestion or insertion of foreign bodies in the gastrointestinal tract is a relatively common phenomenon in infants and children¹. However there are only a few case reports on the literature regarding vaginal burns from alkaline batteries²⁻⁵.

The authors present a case of a 7-year-old girl with severe vaginal burns caused by alkaline batteries.

CASE

A 7-year-old girl presented to the pediatric emergency department in February 2016 with lower abdominal pain and dysuria beginning on that day.

The physical examination revealed a hemodynamically stable and afebrile patient with a soft abdomen. The genitalia inspection revealed an erythematous and slightly edematous vulva with no vaginal discharge. Topical clotrimazole and oral amoxicillin and clavulanic acid was prescribed and the girl was discharged from the emergency department.

Three days later the girl returned to the emergency room due to onset of fever, aggravation of the cyclic abdominal pain with irradiation to the vagina and anus and the occurrence of a brownish vaginal discharge. An abdominal radiography was performed which detected two parallel radio opaque foreign bodies in the vagina (Figure 1). The cause and exact way of the incident were inconclusive by interview. Until then neither the child nor the mother had verbalized/denied the possibility of a foreign body in the vagina. The girl eventually admitted that a boy from school had introduced two alkaline batteries in her vagina but was unable to determine an exact date. We assumed the batteries were inserted at least 6 days before. Since it could be considered sexual abuse screening for sexually transmitted

*Interna do Internato de Ginecologia e Obstetrícia, Maternidade Dr. Alfredo da Costa – Centro Hospitalar de Lisboa Central

**Interna do Internato de Pediatria, Hospital Vila Franca de Xira

***Assistente Hospitalar de Ginecologia e Obstetrícia, Hospital Vila Franca de Xira

Os autores declaram não existir conflito de interesse.

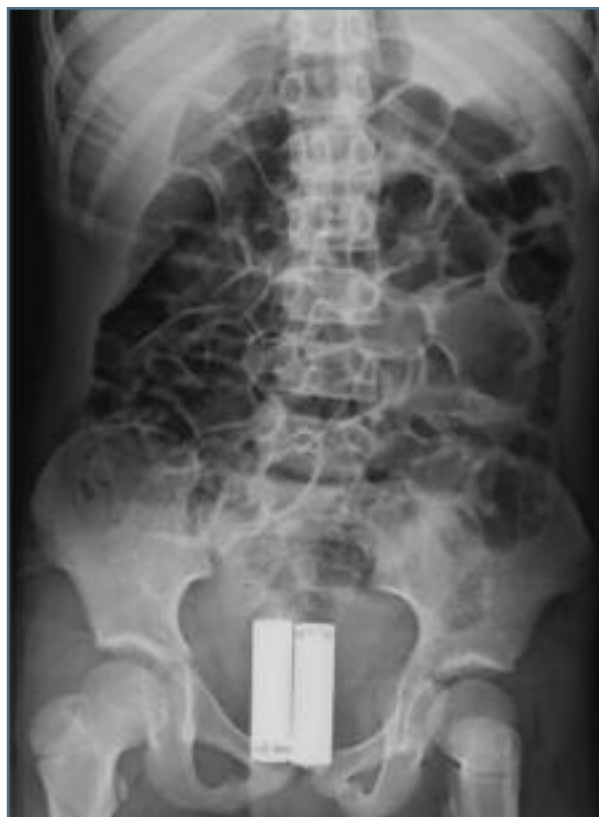

FIGURE 1. Abdominal X-ray revealing two parallel radio opaque foreign bodies in the vagina

diseases was performed (and negative) and the police authorities were informed of the situation.

In order to exclude rectal fistula a blue methylene test was performed with no apparent leakage to the vaginal wall. A pelvic ultrasound (with abdominal probe) demonstrating a full bladder excluded a bladder fistula. Laboratory blood tests revealed leukocytosis ($23.0 \times 10^9/L$) and elevated C-reactive protein (28 mg/dL).

A parental consent was obtained and under general anesthesia the two AA alkaline batteries (Figure 2) were digitally removed (a perforated hymen was previously confirmed) followed by an abundant extravasation of urine. Vaginoscopy was performed revealing two circular, adjacent, necrotic lesions on the posterior cul de sac covered with a brownish eroded vaginal mucosa with matching lesions on the lower third of the vaginal mucosa - corresponding to both ends of the battery (Figure 3). The superficial parts of these lesions were removed with the pressure of saline solution during vaginoscopy and the remain were removed with sterilized gauze. We were unable to eliminate all macroscopic lesions. A digital rectal examination was performed confirming the integrity of the rectal mucosa. Intravenous metronidazole and ceftriaxone were administered for 2 days followed by oral treatment up to 8 days.

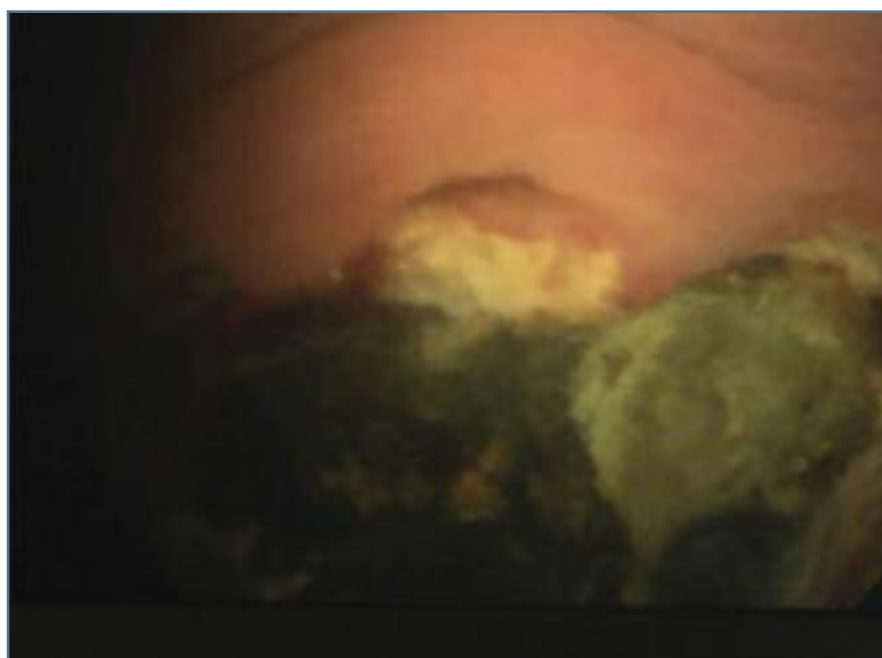


FIGURE 2. Necrotic lesions on the posterior cul de sac during vaginoscopy



FIGURE 3. Two alkaline batteries removed

Following the removal of the alkaline batteries the symptoms disappeared completely except for the vaginal discharge which persisted for a few days.

A vaginal swab revealed no abnormalities.

Two months after the girl was asymptomatic and a vaginal examination revealed no abnormal discharge or signs of synechia.

DISCUSSION

Lower abdominal pain in pediatric population is a frequent symptom imposing a challenging differential diagnosis. However when associated with abnormal vaginal discharge it narrows the possibilities and a thorough clinical examination should be directed towards a definitive diagnosis.

Children represent a particularly difficult patient since they may not provide an accurate history and pa-

rents may be unaware of certain details. Medical imaging such as radiography and ultrasound are a great non-invasive screening tool that could potentially rule out the most serious / fatal conditions.

A foreign body in the vagina is a common cause of vaginal discharge and if undiagnosed or not eliminated in a brief period of time may lead to recurrent urinary tract infection, dermatologic abnormalities, perforation or fistula formation⁶.

Alkaline batteries may produce deleterious effects through different mechanisms: pressure exerted on the tissue, corrosion and the discharges from the battery, specially hydroxide potassium^{2,7}. Timing of vaginoscopy and foreign body extraction are crucial to avoid serious consequences.

Key points

- Children represent a particularly difficult patient since

they may not provide an accurate medical history;

- Lower abdominal pain in pediatric population is a frequent symptom imposing a challenging differential diagnosis;
- A foreign body in the vagina is a common cause of vaginal discharge.

REFERENCES

1. Papsin B, Propst E. Esophageal foreign bodies in infants and children. *Pearson's Thoracic and Esophageal Surgery*. Third edition. 2008; 72:781-791.
2. Semaan A, Klein T, Vahdad M, Boemer T, Pohle R. Severe Vaginal Burns in a 5-Year-Old Girl Due to an Alkaline Battery in th Vagina. *J Pediatr Adolesc Gynecol* 2015: 1-2.
3. Griffin K, Brent R, Vollenhoven B, Swanson A. Vaginal Burn from Alkaline Battery in an 8-Year-Old. *J Pediatr Adolesc Gynecol* 28 (2015) e99-e100.
4. Huppert J, Griffith S, Breech I, et al. Vaginal burn injury due to alkaline batteries. *J Pediatr Adolesc Gynecol* 2009; 22:e133.
5. Dwiggin M, Chan S, Benoit J, Trotman G. Vaginal Burns After Brief Exposure to an Alkaline Battery in a Pre-Pubertal Girl. *J Pediatr Adolesc Gynecol* 29 (2016) 167-187.
6. Nayak S, Witchel S, Sanfilippo J. Vaginal Foreign Body: A Delayed Diagnosis. *J Pediatr Adolesc Gynecol* 27 (2014) e127-e129.
7. Votteler T, Nash J, Rutledge J. The Hazard of Ingested Alkaline Disk Batteries in Children. *JAMA* 1983;249(18):2504-2506.

ENDEREÇO PARA CORRESPONDÊNCIA

Ana Catarina Massa
Maternidade Dr. Alfredo da Costa – Centro Hospitalar de Lisboa Central
Lisboa, Portugal
E-Mail: anacmassa@gmail.com

RECEBIDO EM: 23/08/2017

ACEITE PARA PUBLICAÇÃO: 07/11/2017