

Use of Etonogestrel implant beyond approved duration – A case report

Uso do Implante de Etonogestrel além da duração aprovada – Um caso clínico

Carolina Castro Carvalho¹, Inês Silveira Reis¹, Ana Isabel Machado¹
Maternidade Dr. Alfredo da Costa, Centro Universitário de Lisboa Central, Lisbon, Portugal

Abstract

The contraceptive implant is the most effective method of reversible contraception. Observational and trial data indicate that this method remains effective beyond the initially approved duration of use. We report a case of etonogestrel serum levels above the supposed threshold value for ovulation suppression nine years after implant insertion.

Keywords: Etonogestrel implant; Contraceptive effectiveness; Nexplanon®; Implanon NXT®; Family planning.

Resumo

O implante contraceptivo é o método de contraceção reversível mais eficaz. A evidência obtida através de relatos de casos e estudos prospectivos indica que este método permanece eficaz por mais tempo do que o inicialmente aprovado para uso. Reportamos um caso clínico em que se objetivou um valor sérico de etonogestrel superior ao valor considerado supressor da ovulação nove anos após colocação do implante.

Palavras-chave: Implante de etonogestrel; Eficácia contraceptiva; Nexplanon®; Implanon NXT®; Planeamento Familiar.

INTRODUCTION

Contraceptive implants belong to the group of long-acting reversible contraceptives (LARC), which are the most effective reversible contraceptive methods. There are many advantages to these methods beyond their user-independence, such as desirable side effects, safety in medically complicated patients and cost-effectiveness¹.

The contraceptive implant is placed subdermally and consists of an ethylene vinyl acetate copolymer core that contains 68 mg of the progestagen etonogestrel (ENG)².

The 2001 version of ENG implant, Implanon, was radiolucent. The updated version called Nexplanon/Implanon NXT®, available since late 2010, has a different inserter and contains barium sulfate making it radio-opaque. They were both developed by Merck Sharp & Dohme Limited (MSD).

The existing data suggest that an ENG serum concentration above 90 picograms per milliliter (pg/mL) is necessary to effectively suppress ovulation³.

Officially, implants are approved for three years of use, but studies suggest their effectiveness beyond that period^{1,4,5,6,7}.

In a 2016 multicenter trial conducted by the World Health Organization (WHO), over 200 women used the ENG implant for at least five years, and no pregnancies occurred⁵.

1. Maternidade Doutor Alfredo da Costa, Lisboa.

McNicholas *et al.* also suggested that the implant continues highly-effective for at least two additional years. This study had no documented pregnancies in 291 implant users during the two years of post-expiration follow up⁶.

Some clinical cases seem to corroborate these conclusions. In a 2018 case report, Ribeiro B.C. and colleagues presented a patient who had a deeply inserted implant and a positive serum level of ENG (> 50 pg/ml) 4 years after insertion⁷.

The latest edition of the WHO guidance book, “Family Planning – A global handbook for providers”, refers to the possibility of high effectiveness of ENG implant for five years of use, based on recent studies⁸. In addition, the 2020 consensus document for contraception by the Portuguese Society of Contraception acknowledges the five years efficacy demonstrated by these studies⁹.

The case report here presented refers to a woman with a non-palpable contraceptive implant and a serum concentration of ENG above the threshold value for ovulation suppression nine years after implant insertion. To the extent of our knowledge, there is no other publication until this date of a case with an ENG positive serum test nine years or more after implant insertion.

It was obtained patient consent in order to publish this case report.

CLINICAL CASE

A 32-years-old, G2P1, with no relevant pathological background, was referred to our Family Planning department to extract a non-palpable contraceptive implant. The implant was deeply inserted in the patient's left arm four years before.

As the patient did not know about the type of implant inserted, we started by performing both arm and thorax radiography. After that, a left upper limb ultrasound exam. All methods failed to localize the implant, which indicated to us that this was a non-radio-opaque implant and could have migrated.

The next step was an upper limb magnetic resonance (MRI), but the patient missed the appointments and did not come back until five years later. The patient came back because she was trying to get pregnant and was not successful so far.

Since the patient assured us that she could feel the implant in the first years after insertion, we requested a serum ENG determination. The result was 104.20 pg/mL of ENG, which was above the supposed threshold value for ovulation suppression (90 pg/mL)³.

Subsequently, we performed an MRI of the left upper limb that located the implant in the superficial fascia on the left arm's inner side, the distal end situated 13 cm from the olecranon's vertex.

After marking the extraction site with a dermatographic pen, guided by ultrasound, we successfully removed the contraceptive implant.




FIGURE 1. Left upper limb MRI. Transverse section.

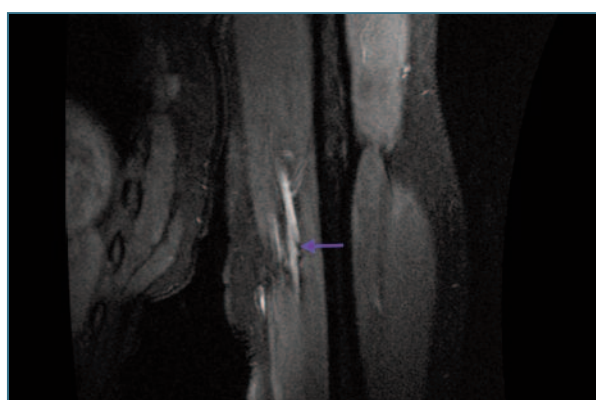


FIGURE 2. Left upper limb MRI. Longitudinal section.

DISCUSSION

Current studies indicate that contraceptive implants are highly effective for at least five years of use^{1,5,6}. Nevertheless, until this moment, the implant manu-

facturer or scientific societies have no official recommendation to extend the duration of use to five years.

In this clinical case, the patient had a positive ENG blood level, above the threshold for ovulation inhibition, nine years after insertion, which is six years after the initial approved duration of use and four years after the period indicated by the more recent studies.

The extended use of the ENG implant could reduce the frequency of removal/insertion procedures, save resources and time of health personal, and improve implant cost-effectiveness while improving convenience for women⁵.

The case we report here is in agreement with others already published and reinforces the evidence that implants are effective for longer than the recommended duration of use. We are aware that one single case is not enough to recommend changes in practice. However, it helps to call attention for further investigation of this issue, preferentially through prospective studies, with focus on the pharmacokinetic of ENG serum levels, variability in body mass index, potential drug interactions and durability of devices.

REFERENCES

1. McNicholas C, Maddipati R, Zhao Q, et al. Use of the Etonogestrel Implant and Levonorgestrel Intrauterine device beyond U.S. Food and Drug Administration – Approved Duration. *Obstet Gynecol.* 2015; 125(3): 599-604. DOI:10.1097/AOG.0000000000000690.
2. Committee on Practice Bulletins – Gynecology, Long-Acting Reversible Contraception Work Group. Practice bulletin no. 186. Long-acting reversible contraception: implants and intrauterine devices. *Obstet Gynecol.* 2017;130:e251-e269.
3. Diaz S, Pavez M, Moo-Young AJ, et al. Clinical Trial with 3-keto-desogestrel subdermal implants. *Contraception.* 1991; 44:393-408. DOI: 10.1016/0010-7824(91)90030-j
4. Ali M, Bahamondes L, Bent Landoulsi S. Extended effectiveness of the etonogestrel-releasing contraceptive implant and the 20 mg levonorgestrel-releasing intrauterine system for 2 years beyond U.S. Food and Drug Administration product labeling. *Glob Health Sci Pract.* 2017; 5(4):534-539. DOI: 10.9745/GHSP-D-17-00296
5. Ali M, Akin A, Bahamondes L, et al; WHO study group on subdermal contraceptive implants for women. Extended use up to 5 years of the etonogestrel-releasing subdermal contraceptive implant: comparison to levonorgestrel-releasing subdermal implant. *Human Reproduction.* 2016; Vol.31: 2491-2498. DOI: 10.1093/humrep/dew222
6. McNicholas C, Swor E, Wan L, et al. Prolonged use of the etonogestrel implant and levonorgestrel intrauterine device: 2 years beyond Food and Drug Administration approved duration. *Am J Obstet Gynecol.* 2017, e1-6. 216:586. DOI:https://doi.org/10.1016/j.ajog.2017.01.036
7. Ribeiro BC, Nogueira-Silva C, Afonso H, et al. Use of etonogestrel implant beyond approved duration: prolonged contraceptive effectiveness, *The European Journal of Contraception & Reproductive Health Care* 2018. DOI:10.1080/13625187.2018.1501799
8. World Health Organization Department of Reproductive Health and Research (WHO/RHR) and Johns Hopkins Bloomberg School of Public Health/Center for Communication Programs (CCP), Knowledge for Health Project. *Family Planning: A Global Handbook for Providers* (2018 update). Baltimore and Geneva: CCP and WHO, 2018.
9. Sociedade Portuguesa de Ginecologia [Portuguese Gynecology Society], Sociedade Portuguesa de Contraceção [Portuguese Society of Contraception]. *Consenso sobre Contraceção 2020*; 2020 Jan. 136 p.
10. Thaxton L, Lavelanet A. Systematic review of efficacy with extending contraceptive implant duration. *Int J Gynaecol Obstet.* 2019 Jan; 144(1): 2-8. DOI:10.1002/ijgo.12696
11. Amaral PI, Correia L, Reis IS, Machado AI. Non palpable Implanon rod – strategies for their localization and removal. *Acta Obstet Ginecol Port* 2013; 7(4): 256-60.

AUTHORS CONTRIBUTIONS

Author 1 – Member of the clinical team in charge of the case. Responsible for the non-systematic review of literature and wrote the paper under supervision from author 3.

Author 2 – Member of the clinical team in charge of the case. Interpretation of clinical data.

Author 3 – Principal assistant in charge of the case. Supervision of manuscript writing.

CONFLICTS OF INTEREST

The authors have no conflict of interest.

ENDEREÇO PARA CORRESPONDÊNCIA

Carolina Castro Carvalho

E-mail: mcarolina.accarvalho@gmail.com

RECEBIDO EM: 12/11/2021

ACEITE PARA PUBLICAÇÃO: 10/02/2022