

Secondary breast angiosarcoma – A consequence of breast conservative surgery?

Angiosarcoma secundário da mama – uma consequência da cirurgia conservadora?

Mariline Oliveira¹, Ana Carolina Rocha¹, Maria João Guardado², José Fiel¹, Maria Madalena Nogueira¹
Hospital de Santarém EPE

Abstract

Breast angiosarcoma is an aggressive malignancy with a high recurrence rate and poor overall survival. It is the type of sarcoma most related with previous radiotherapy. The diagnosis is still a challenge because of the long latency period until its development and also because of its subtle and apparently benign presentation. There is still lack of evidence about treatment. We report a case of a 69 year-old women, who has had breast-conserving surgery and adjuvant radiotherapy after a breast invasive carcinoma, and developed a high grade angiosarcoma nine years after the first diagnosis.

Keywords: Breast neoplasms; Breast-conserving surgery; Radiotherapy.

INTRODUCTION

Breast sarcoma is a severe malignancy of parenchymal origin, which represents less than 1% of all breast malignancies¹⁻³. Given the rarity of primary angiosarcoma, risk factors are difficult to determine. However, there is an established association between secondary angiosarcoma and previous radiation therapy to the breast or the chest wall, or chronic lymphedema of the upper limbs (Stewart-Treves Syndrome)^{1-5,6}. The widespread adoption of breast-conserving surgery and adjuvant radiotherapy in the management of primary breast cancer has been accompanied by a steady increase in the incidence of secondary breast angiosarcomas²⁻⁴. Nowadays it is considered a late complication of radiation treatment with a cumulative incidence of 0,9/1000 cases in 15 years⁵. In opposite to other breast sarcomas, secondary breast angiosarcoma is usually found in older women (60/70 years of age)^{3,4}. The median latency period between radiation for breast cancer and subsequent diagnosis is about six years, but the risk remains for, at least, 20 years^{2,3,5}. It is not known how new radiotherapy techniques, such as the delivery of intensity-modu-

lated radiation therapy (IMRT), may influence the risk of secondary angiosarcoma. In 1948 Cahan presented the criteria to define a radiation induced lesion: previous radiation exposition of the area, long latency period between radiation exposure and lesion manifestation, different histology between the new lesion and the primary malignancy that elicited the treatment.⁷ Since there is a rapid local progression of the disease and a high risk of distant metastasis, the prognosis is poor^{3,4}.

We report a case of a high grade angiosarcoma diagnosed nine years after a breast invasive carcinoma treated with breast-conserving surgery and radiotherapy.

CASE REPORT

A 69 year-old woman with a previous breast-conserving surgery followed by radiation therapy after an invasive ductal carcinoma on the right breast was referred to our department with a lump at the previous surgery scar. The mammogram showed a high density area, which was biopsied and did not reveal malignancy (Figure 1). On Magnetic Resonance Imaging (MRI) there was a regular mass with 4,5 cm, involving the skin but far from the underlying muscle (Figure 2). The biopsy revealed a high grade angiosarcoma. Axillary or

1. Hospital Santarém EPE.

2. Joaquim Chaves Saúde – Clínica de Radioncologia de Santarém.

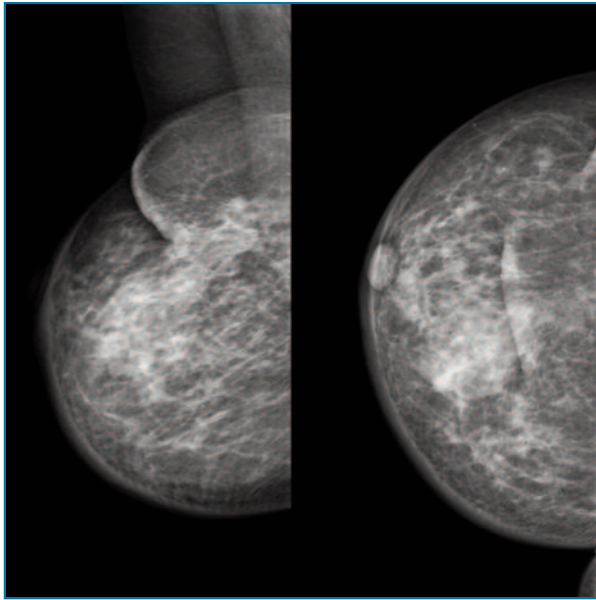


FIGURE 1. Mammogram showing a high density unspecific area on the right breast.

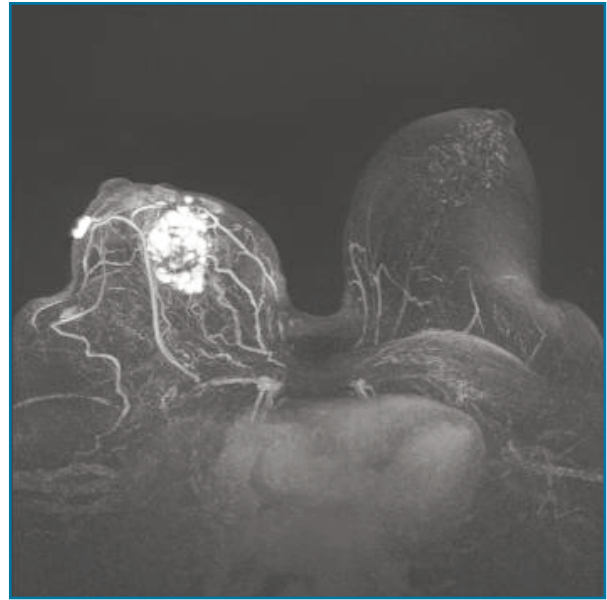


FIGURE 2. MRI showing a regular mass with 4,5 cm, involving the skin but not the underlying muscle of the right breast.

distant metastasis were not detected. After discussion in a multidisciplinary set, a mastectomy with excision of the affected skin was performed with immediate reconstruction. The sentinel node biopsy was negative (OSNA® assay). Pathology confirmed the high grade angiosarcoma, with negative surgical margins. Nine months later, the patient presented with back and abdominal pain associated with asthenia. The abdominal computed tomography scan (CT) revealed multiple nodular hepatic and splenic lesions. The bone scintigraphy showed multiple lytic lesions consistent with malignancy located in D7-L1, left humerus head and third and fourth ribs on the left. Due to the extensive metastazation, the patient was referred to palliation and died two months later.

DISCUSSION

Breast angiosarcoma usually presents as single or multiple ecchymotic macular or purplish macular cutaneous lesion in the breast or an edematous upper extremity^{3,5}. Findings on mammography are frequently nonspecific and unsuspecting^{3,4,8,9}. MRI enables the diagnosis suspicion and provides information on the extent of disease, including the involvement of the skin and the deep fascia and pectoralis muscle^{4,8}. If a patient

with previous history of breast malignancy presents with a palpable mass on the breast or a skin lesion, a biopsy should be pursued, despite inconclusive imaging findings^{3,8}.

Even though regional lymph node metastasis are more common with angiosarcoma than with other sarcomas, the incidence is still low⁸. Yet, searching for axillary involvement is still recommended. All patients should be evaluated for spread of metastatic disease, particularly in bones, lungs and liver. CT of the chest and the abdomen, as well as a bone scintigraphy are recommended⁴.

Since angiosarcoma is a rare presentation of breast malignancy, treatment options arise from small retrospective and non-randomized studies. The first approach entails a multidisciplinary discussion. Surgery seems to be the only potentially curative option and adequate resection margins (at least 2-4 cm) is the single most important determinant of long-term survival with breast sarcomas^{3,8}. Since angiosarcomas are usually large and extensive, mastectomy is considered the standard approach. However, even with complete resections with negative margins (R0), the recurrence risk is not negligible⁹. With respect to axillary involvement, biopsy of the sentinel node is suggested when the axillary investigation is negative. There are no validated conclusions on adjuvant and neo-adjuvant therapies, specially when

dealing with radiation-induced malignancies^{1,3}. The decision should be customized depending on patient status and the risk/benefit balance of the treatment.

Angiosarcomas apparently behave more severely than other breast sarcomas^{2,3,9}. The size of the tumor and the histologic stage seem to be the most important prognostic determinants^{8,9}. Since high grade angiosarcomas with high risk of local and distant metastatic spreading and high recurrence rate are the most common presentation, prognosis is usually poor. The overall survival after surgical treatment in patients with no metastasis is about four years^{1,2}.

In conclusion, even though the risk of developing a secondary angiosarcoma after radiation therapy might increase with the widening of breast-conserving surgery, the potential benefit of radiation therapy is, for now, frankly higher than the residual risk of developing a treatment-related angiosarcoma. In patients with previous radiation therapy there should be a close follow-up of new symptoms and findings, even if not suspicious of malignancy. An early diagnosis might lead to a better prognosis. Once again, the small number of cases reported and the scarce clinical evidence enhance the challenging approach to diagnosis and treatment of angiosarcoma.

REFERENCES

1. S. Hasan, et al. Management trends and outcomes of breast angiosarcoma: Is breast conservation feasible?. *Breast J.* 2019; 00:1-5
2. Mery CM, George S, Bertagnolli MM, et al. Secondary sarcomas after radiotherapy for breast cancer: sustained risk and poor survival. *Cancer.* 2009;115:4055 – 4063
3. M. Taffurelli et al. Secondary breast angiosarcoma: A multi-centre retrospective survey by the national Italian association of Breast Surgeons (ANISC). *The Breast,* 45 (2019) 56-60
4. S. Shah et al. Radiation-Associated Angiosarcoma of the Breast - Clinical and Pathologic Features. *Arch Pathol Lab Med - Vol 140,* 2016
5. Yap J et al. Sarcoma as a second malignancy after treatment for breast cancer. *Int J Radiation Oncology Biol Phys.* 2002; 52 (5): 1231-72
6. Mentzel T et al. Post-radiation cutaneous angiosarcoma after treatment of breast carcinoma is characterized by MIC amplification in contrast to atypical vascular lesions after radiotherapy and control cases: clinicopathological, immunohistochemical and molecular analysis. *Mod Pathol.* 2012; 25.
7. Cahan WG, Woodard HQ. Sarcoma arising in irradiated bone-report 11 cases. *Cancer,* 1948; 1(1):3-29.
8. G.R.Sheth,L.D.Cranmer,B.D.Smith,L.Grasso-LeBeau,and J. E. Lang. Radiation-induced sarcoma of the breast: a systematic review, *The Oncologist,* vol. 17, no. 3, pp. 405–418, 2012.
9. E. Ghareeb et al. Primary and Radiation-induced Breast Angiosarcoma - Clinicopathologic Predictors of Outcomes and Impact of Adjuvant Radiation Therapy. *Am J Clin Oncol* 2014.

ENDEREÇO PARA CORRESPONDÊNCIA

Mariline Oliveira
E-mail: m.eudora@gmail.com

RECEBIDO EM: 10/02/2021

ACEITE PARA PUBLICAÇÃO: 03/10/2021