

Cervical elongation caused by cervical fibroid mimicking uterine prolapse

Prolapso uterino ou alongamento cervical causado por mioma?

Marília Lima Freixo,¹ Anabela Melo,² Sílvia Torres²
Serviço de Ginecologia e Obstetrícia, Centro Hospitalar Tâmega e Sousa

Abstract

Growing cervical masses could drag the cervix, predisposing to cervical elongation and prolapse. The differential diagnosis of protrusion of a large vaginal mass includes a uterine or vaginal vault prolapse, a pedunculated uterine leiomyoma or leiomyosarcoma, a uterine stromal tumor or a giant polyp. The authors report a case of an atypical presentation of cervical fibroid with cervical elongation mimicking cervical malignancy.

Keywords: Cervical fibroid; Cervical elongation.

Resumo

Massas cervicais de grandes dimensões podem predispor ao prolapso do colo do útero por alongamento. O diagnóstico diferencial inclui prolapso uterino ou de cúpula vaginal, leiomioma uterino pediculado ou leiomiossarcoma, tumor estromal uterino ou pólipio gigante. Os autores relatam um caso de apresentação atípica de um mioma cervical com alongamento cervical simulando neoplasia cervical.

Palavras-chave: Mioma cervical; Alongamento cervical.

Uterine prolapse and cervical elongation can occur due to several mechanisms: first, the prolapsed uterus could have had longer cervix; second the descent of the developing prolapse can induce cervical elongation through downward traction¹. Also, growing cervical masses can drag the cervix, predisposing to cervical elongation and prolapse².

Cervical fibroid usually manifests as a solid-bulky cervical mass with smooth surface. However, in some cases the fibroid can degenerate or erode, fragilizing the surface, leading to bleeding and necrosis³.

We present a case of cervical fibroid with cervical elongation resembling malignancy.

A 46-year-old woman, Gravida 1, Para 1, was referred to a gynecology appointment for a presumed non-reducible uterine prolapse. Her medical or surgical history was unremarkable, and she was under no medication.

The patient reported a history of daily metrorrhagia and a progressive growing mass protruding from the vagina, over the past 4 months.

Clinical examination confirmed the presence of a nontender cervix with a protruding exofitit mass with 10 cm coming from the posterior lip of the cervix with necrosis (Figure 1). Vaginal examination showed well-positioned vaginal pouches and an apparent hypertrophic elongation of the cervix, occupying the entire length of the vagina.

1. Médica Interna de Formação Específica, Serviço de Ginecologia e Obstetrícia, Centro Hospitalar Tâmega e Sousa, Penafiel, Porto, Portugal.

2. Assistente Hospitalar Graduada, Serviço de Ginecologia e Obstetrícia, Centro Hospitalar Tâmega e Sousa, Penafiel, Porto, Portugal.

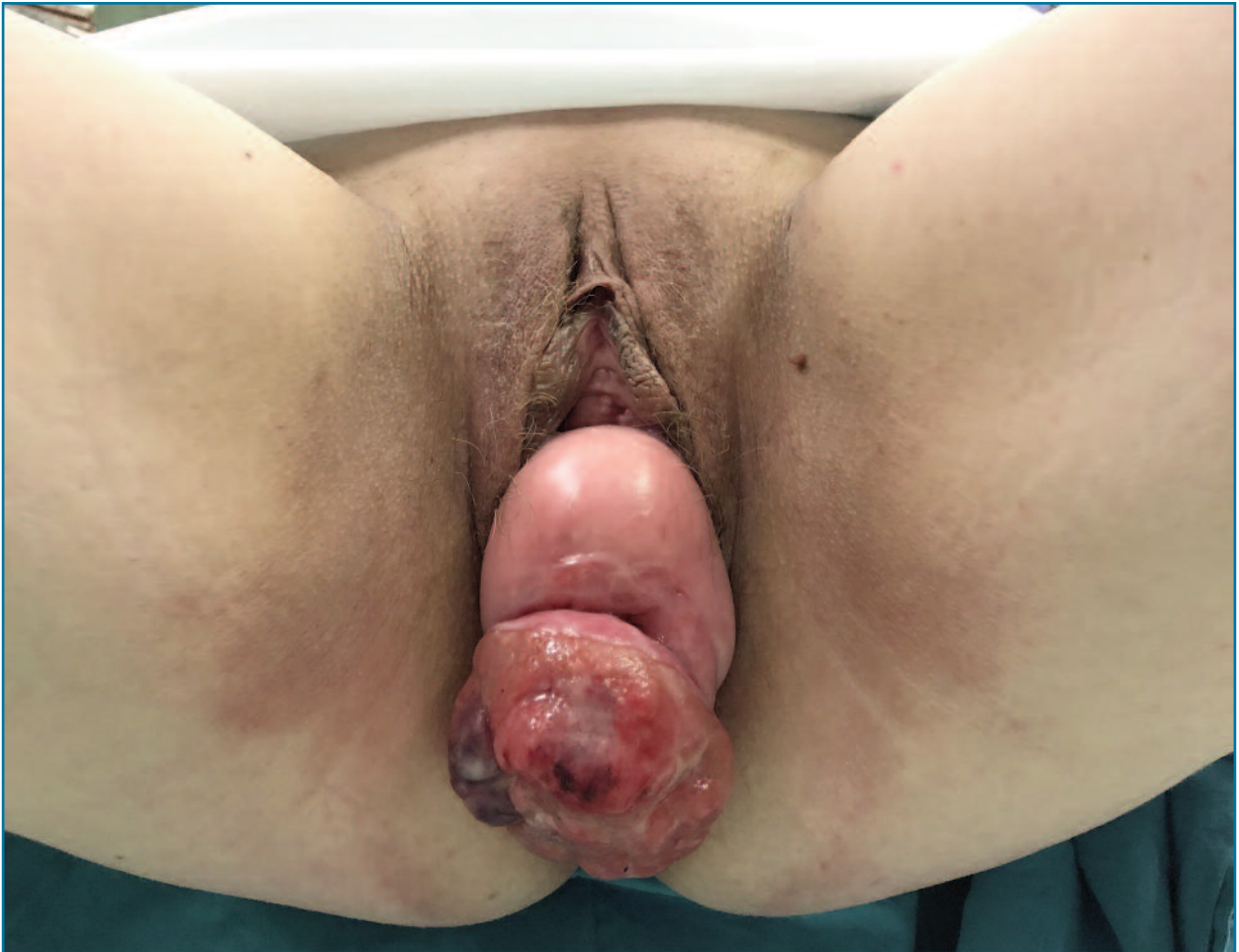

FIGURE 1. Prolapsed mass with some necrotic and reddish surface resembling cervical malignancy.

Transvaginal ultrasound revealed a nonprolapsed augmented-sized uterus (120x52x63 mm).

A biopsy of the lesion was performed, revealing fragments with fibrinoleukocyte exudate and fibroconnective stroma, and no signs of malignancy.

The patient was admitted for surgical excision. During admission, further enlargement of the protruding mass with bleeding and ischemic-type areas was observed. A Laparoscopy-assisted vaginal hysterectomy (LAVH) was performed because it was the easiest approach, as the uterus was non-prolapse, allowing for bilateral salpingectomy. (Figure 2).

Post operative period was unremarkable and the patient was discharged on the following day.

Histopathological examination confirmed the diag-

nosis of a cervical leiomyoma, exocervical hyperplasia without atypia and extensive ulceration.

Growing cervical masses can drag the cervix, predisposing to cervical elongation and prolapse. Diagnosis of prolapsed cervical leiomyomas can be challenging, as pelvic examination may not be able to exclude a uterine prolapse or a uterine inversion⁴.

Moreover, in our case, clinical presentation was mimicking a cervical malignancy, as it presented as a fragile cervical mass with some bleeding and necrosis.

Cervical fibroids protruding through vagina are usually pedunculated. Nevertheless, in our case, the fibroid was not pedunculated, presenting as a bulky mass on the cervical tissue, mimicking a cervical malignancy. Thus, biopsy is compulsory to establish the

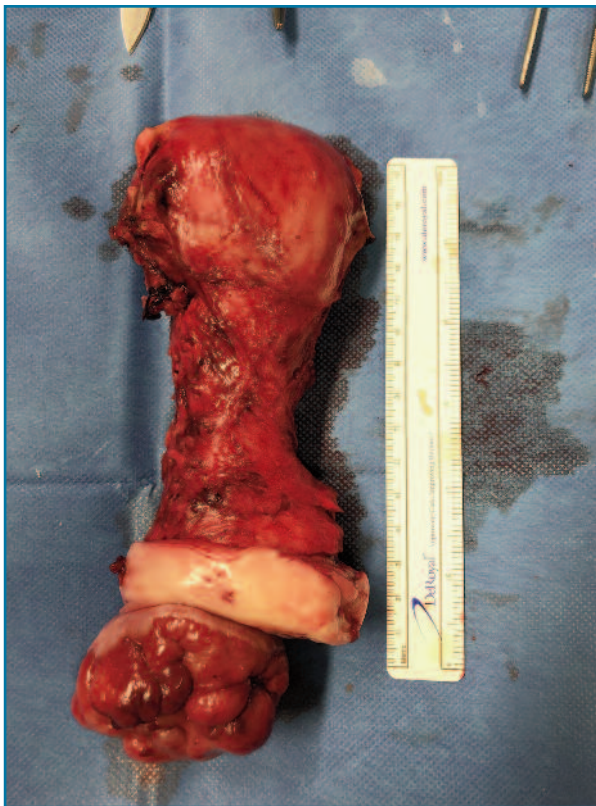


FIGURE 2. Taken out the uterus with elongated cervix and cervical fibroid.

diagnosis and to guide the decision-making process. As our preoperative biopsy did not show signs of malignancy, our approach was vaginal. Manchester Fothergill is considered an affective procedure for cervical elongation without pelvic organ prolapse since it allows shorter surgery length and less surgical complications, compared to vaginal hysterectomy⁵.

In our case, the patient expressed a desire to underwent hysterectomy and for that reason we chose to perform a LAVH.

We highlight this case because of the atypical presentation of cervical elongation with cervical fibrinoids, without uterine prolapse associated, with rare cases found on the literature.

REFERENCES

1. Berger MB, Ramanah R, Guire KE, DeLancey JO. Is cervical elongation associated with pelvic organ prolapse? *Int Urogynecol J.* 2012 Aug;23(8):1095-103. doi: 10.1007/s00192-012-1747-6. Epub 2012 Apr 14. PMID: 22527546; PMCID: PMC3396731.
2. Gurung G, Rana A, Magar DB. Utero-vaginal prolapse due to portio vaginal fibroma. *J Obstet Gynaecol Res.* 2003 Jun;29(3):157-9. doi: 10.1046/j.1341-8076.2003.00093.x. PMID: 12841699.
3. Agha RA, Sohrahi C, Mathew G, Franchi T, Kerwan A, O'Neill N; PROCESS Group. The PROCESS 2020 Guideline: Updating Consensus Preferred Reporting Of CasE Series in Surgery (PROCESS) Guidelines. *Int J Surg.* 2020 Dec;84:231-235. doi: 10.1016/j.ijsu.2020.11.005. Epub 2020 Nov 12. PMID: 33189880.
4. Golan A, Zachalka N, Lurie S, Sagiv R, Glezerman M. Vaginal removal of prolapsed pedunculated submucous myoma: a short, simple, and definitive procedure with minimal morbidity. *Arch Gynecol Obstet.* 2005 Jan;271(1):11-3. doi: 10.1007/s00404-003-0590-x. Epub 2004 Mar 4. PMID: 14999510.
5. Park YJ, Kong MK, Lee J, Kim EH, Bai SW. Manchester Operation: An Effective Treatment for Uterine Prolapse Caused by True Cervical Elongation. *Yonsei Med J.* 2019 Nov;60(11):1074-1080. doi: 10.3349/ymj.2019.60.11.1074. PMID: 31637890; PMCID: PMC6813150.

AUTHORS' CONTRIBUTION

Conceptualization: Marília Freixo, Anabela Melo, Sílvia Torres

Methodology: Marília Freixo

Writing – Original draft: Marília Freixo

Writing – Review: Marolia Freixo, Anabela Melo, Sílvia Torres

PATIENT CONSENT

The patient gave permission to use clinical information and photographic material in this publication.

CONFLICTS OF INTEREST

There are no conflicts of interest.

CORRESPONDENCE TO:

Marília Lima Freixo

E-mail: mariliafreixo@gmail.com

<https://orcid.org/0000-0001-8583-9072>

RECEIVED: 30/07/2022

ACCEPTED: 27/10/2022